

Sustained remission after ABVD treatment for interdigitating dendritic cell sarcoma

Grzegorz Helbig¹, Ryszard Wichary¹, Jacek Pająk², Maria Budny³, Małgorzata Makowska³, Klaudyna Machura³, Marcin Kubeczko³, Sławomira Kyrz-Krzemień¹

¹Department of Haematology and Bone Marrow Transplantation, Silesian Medical University, Katowice, Poland

²Department of Pathology, Silesian Medical University, Katowice, Poland

³Students' Research Group, Department of Haematology and Bone Marrow Transplantation, Silesian Medical University, Katowice, Poland

Contemp Oncol (Pozn) 2015; 19 (1): 83–85
DOI: 10.5114/wo.2014.43974

Interdigitating dendritic cell sarcoma (IDCS) is an extremely rare neoplastic proliferation of dendritic cells [1]. EBV and HSV8 viral infections are thought to be involved in its pathogenesis, but understanding their role requires further studies [2]. IDCS usually affects adults with a median age at diagnosis of 51 years. Clinical manifestation usually includes lymphadenopathy, but extranodal presentation has also been reported [1, 3, 4]. Up-to-date studies on IDCS treatment and outcome are based on single case reports or very small series [1–6]. It was demonstrated that this neoplasm displays an aggressive clinical course, but a standard therapeutic approach has not been established so far. Different treatment modalities have been attempted, but they have mostly been ineffective [6, 7]. Herein, we report on a 22-year-old female with IDCS manifested as peripheral and mediastinal lymphadenopathy, who responded completely to ABVD (adriamycin, bleomycin, vinblastine, dacarbazine).

A 22-year-old, previously healthy female was referred to our Haematological Department with a diagnosis of IDCS. Eight months prior to admittance she accidentally noticed an enlarged cervical lymph node. No general symptoms were present at that time. The diagnostic work-up was started. Common reactive causes of lymphadenopathy were carefully excluded. Computed tomography (CT) scan of the neck revealed bilaterally enlarged lymph nodes (size 4.5 cm × 3.5 cm). Chest X-ray and CT scan of the abdomen did not detect any abnormalities. Positron emission tomography (PET) scan performed in February 2010 showed increased glucose uptake in the right cervical area. Histological examination of the excised lymph node was done and the study revealed sheets of spindled cells with a whorled pattern. The nuclei of these cells were spindled or ovoid (Fig. 1). There were some multinucleate cells. The cytoplasm was slightly eosinophilic. Among these spindled cells, there were numerous lymphocytes and plasma cells. Necrosis was absent. The neoplastic cells were strongly positive for S-100 protein (Fig. 2), fascin (Fig. 3) and vimentin. They weakly expressed CD68 (Fig. 4) and CD45 antigens. CD1a and CD30 were absent, whereas expression of CD4 was positive. A preliminary diagnosis of IDCS was proposed. Due to the rarity of this disease, the lymph node was examined by two other patholo-

gists and the final diagnosis was established three months later. On admission to our Centre the physical examination was normal except the enlargement of the right cervical lymph node. Blood tests showed haemoglobin concentration of 12.8 g/dl, white blood cell (WBC) count of $6.8 \times 10^9/l$ and platelet count of $245 \times 10^9/l$. Leukocyte differential was normal. Lactate dehydrogenase (LDH) activity and β_2 -microglobulin (B2M) levels were within normal ranges (140 IU/l and 1.6 ng/ml, respectively). Biochemistry panel was normal. Viral studies were negative for HBV, HCV, CMV and EBV. The test for HSV8 was not performed. Bone marrow trephine biopsy revealed no abnormalities. Repeated CT scan of the chest done in May 2010 demonstrated two “new” tumour masses; in the retrosternal area (size 10 cm × 1.5 cm) and in the aorto-pulmonary window (size 2 cm × 2 cm). The patient started chemotherapy consisting of an ABVD regimen (adriamycin 25 mg/m², bleomycin 10 mg/m², vinblastine 6 mg/m², dacarbazine 375 mg/m²) on days 1 and 15 in a 28-day cycle. She was given 6 cycles of ABVD and showed good tolerance. PET scan was negative after the completion of chemotherapy. Currently, more than two years after ABVD, she remains in complete clinical remission.

The IDCS is an extremely rare neoplasm arising from antigen presenting cells. To date, only about 80 cases of IDCS, including one paediatric series, have been reported [8, 9]. Constitutional symptoms are rare and are usually associated with inferior prognosis. They may include weight loss, fever, night sweats and fatigue [1, 10]. Most patients have lymph node involvement [11], and extranodal manifestation can occur rarely, including the parotid gland [5], spleen [2], pleura [4], tonsil [12], skin [13] or small intestine [14].

Initially, our patient presented with solitary cervical lymph node involvement, and such manifestation is the most common [1, 3]. However, mediastinal presentation has not been reported so far. Constitutional symptoms were absent at diagnosis. It should be mentioned that the age of onset was lower when compared to that reported in the literature [10]. Due to the rarity of this neoplasm and its histological similarity to other soft tissue tumours, diagnosis of IDCS is difficult and often delayed. The diagnosis is based on histological examination of the involved organ, which demonstrates proliferation of spindle to oval

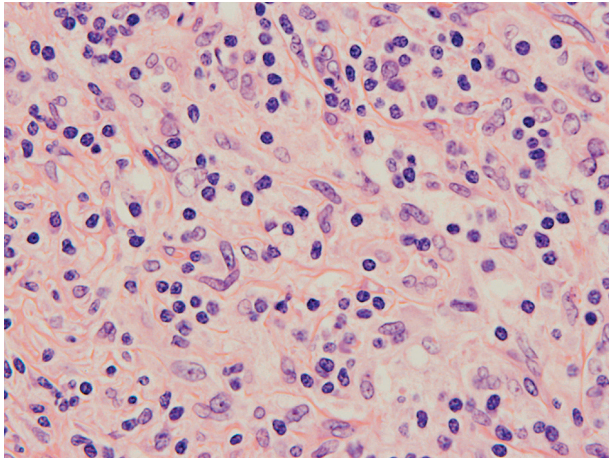


Fig. 1. Spindle shaped cells with spindled nuclei and eosinophilic cytoplasm. Original magnification 400×

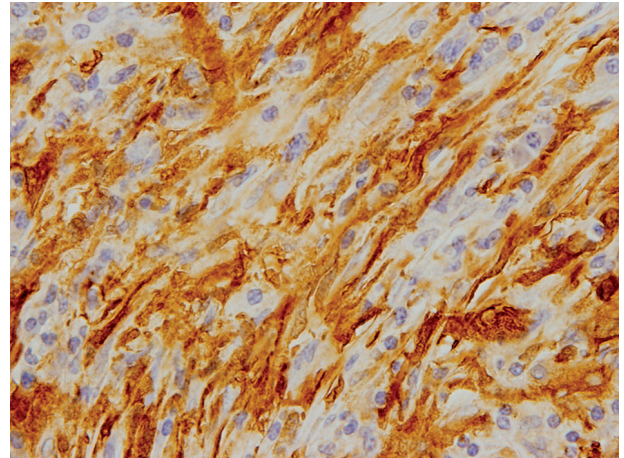


Fig. 2. A positive staining for S100 protein. Original magnification 400×

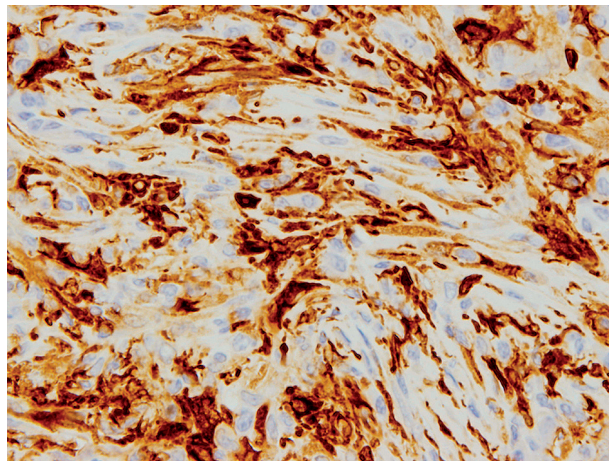


Fig. 3. A fascin-positive staining. Original magnification 400×

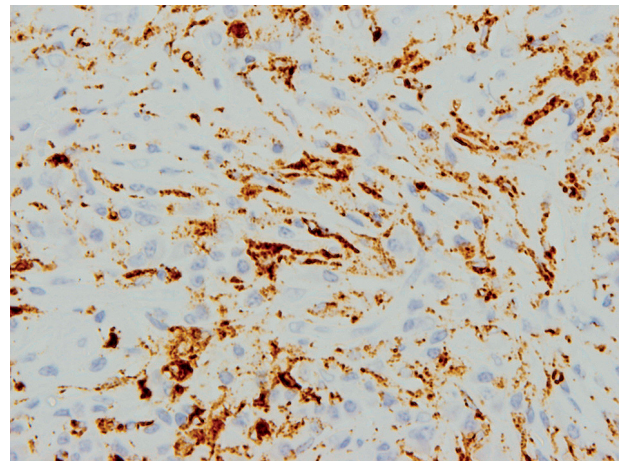


Fig. 4. A CD68-positive staining in single dendritic cells. Original magnification 400×

cells with fascicular or whorled growth pattern. The nuclei are round to ovoid and may show indentations. Due to this atypical histological appearance, immunophenotyping is required for final diagnosis [10, 11]. Our case demonstrated the morphological and immunophenotypical features of IDCS. Nevertheless, due to its rarity, the tissue specimens were examined by two independent pathologists and the final diagnosis was significantly deferred. It should be mentioned that the differential diagnosis of IDCS is broad and may include several neoplastic and non-neoplastic conditions [10].

The treatment of IDCS includes surgery, radiotherapy and chemotherapy. The results of the therapy are unsatisfactory and optimal treatment has not been established so far. Radical surgery has been the mainstay treatment for patients with localised disease. Several cases were reported with successful outcome, but rapid relapses have also been observed [2, 11, 14]. Disseminated IDCS requires more intensive therapeutic management, usually combined chemotherapy, but a standard approach is yet to be established. The schema primarily used for lymphoma have been tested, but the results were inconclusive [4]. Most

patients were treated with CHOP (cyclophosphamide, hydroxydaunorubicin, oncovin, prednisone) regimen [1, 3, 12].

We present a patient who achieved a complete response after ABVD regimen, despite disseminated disease at presentation. A similar case has been reported in the literature, but the patient was older (a 44-year-old female) and the disease was disseminated below the diaphragm, including the small bowel and the liver [6]. Resistance to chemotherapy was associated with dismal outcome, even when autologous stem cells transplantation (ASCT) was performed [7]. It should be mentioned that we were unable to find any other descriptions of ASCT for IDCS in the literature.

In conclusion, we presented an IDCS case in a young female who has remained in complete clinical remission for more than two years after cessation of six cycles of ABVD. Due to disseminated disease, we consider ASCT as remission consolidation; nevertheless, the patient refused this procedure. Further studies with larger groups of patients are needed to evaluate the most effective treatment strategy in IDCS.

The authors declare no conflict of interest.

References

1. Gaertner EM, Tsokos M, Derringer GA, Neuhauser TS, Arciero C, Andriko JA. Interdigitating dendritic cell sarcoma. A report of four cases and review of the literature. *Am J Clin Pathol* 2001; 115: 589-97.
2. Kawachi K, Nakatani Y, Inayama Y, Kawano N, Toda N, Misugi K. Interdigitating dendritic cell sarcoma of the spleen: report of a case with a review of the literature. *Am J Surg Pathol* 2002; 26: 530-7.
3. Zhou ZY, Sun RC, Yang SD, Liang JB, Rui J, Pan MH. Interdigitating dendritic cell tumor of the lymph node in the right submaxillary region: a case report and review of the literature. *Int J Surg Pathol* 2011; 19: 88-92.
4. Han HS, Lee OJ, Lim SN, et al. Extranodal interdigitating dendritic cell sarcoma presenting in the pleura: a case report. *J Korean Med Sci* 2011; 26: 304-7.
5. Efuno G, Sumer BD, Sarode VR, Wang HY, Myers LL. Interdigitating dendritic cell sarcoma of the parotid gland: case report and literature review. *Am J Otolaryngol* 2009; 30: 264-8.
6. Olnes MJ, Nicol T, Duncan M, Bohlman M, Erlich R. Interdigitating dendritic cell sarcoma: a rare malignancy responsive to ABVD chemotherapy. *Leuk Lymphoma* 2002; 43: 817-21.
7. Adam Z, Vesely K, Krejci M, et al. Interdigitating dendritic cell sarcoma of lower extremities resistant to high dose chemotherapy BEAM with peripheral blood stem cell transplantation. *Vnitr Lek* 2009; 55: 147-57.
8. Janfeng Z, Weixun Z, Chunmei B, Yanping Z, Yuzhou W. Interdigitating dendritic cell sarcoma: case report with review of the literature. *Onkologie* 2011; 34: 634-7.
9. Pillay K, Solomon R, Daubenton JD, Sinclair-Smith CC. Interdigitating dendritic cell sarcoma: a report of four pediatric cases and review of the literature. *Histopathology* 2004; 44: 283-91.
10. Ye Z, Liu F, Cao Q, Lin H. Interdigitating dendritic cell sarcoma of lymph node mimicking granuloma: a case report and review of the literature. *Pol J Pathol* 2011; 62: 274-7.
11. Perkins SM, Shinohara ET. Interdigitating and follicular dendritic cell sarcomas: A SEER analysis. *Am J Clin Oncol* 2012; 36: 395-8.
12. Kim SY, Kang JH, Chun SH, et al. Interdigitating dendritic cell sarcoma of the tonsil. *Asia Pac J Clin Oncol* 2010; 6: 144-8.
13. Lee JC, Christensen T, O'Hara CJ. Metastatic interdigitating dendritic cell sarcoma masquerading as a skin primary tumor: a case report and review of the literature. *Am J Dermatopathol* 2009; 31: 88-93.
14. Ishihara S, Honda Y, Asato T, et al. Interdigitating dendritic cell sarcoma of the ileum recurred in multiple lymph nodes and duodenum three years after operation without chemotherapy. *Pathol Res Pract* 2010; 15: 514-8.
15. Boldin I, Brix-Grünwald G, Scarpatetti MM, Beham-Schmid C, Klein A. Interdigitating dendritic cell sarcoma of the eyelid with a rapidly fatal course. *Arch Ophthalmol* 2008; 126: 738-40.

Address for correspondence

Grzegorz Helbig

Department of Haematology
and Bone Marrow Transplantation
Silesian Medical University
Dąbrowskiego 25
40-032 Katowice, Poland
e-mail: ghelbig@o2.pl

Submitted: 18.10.2012

Accepted: 06.02.2013